

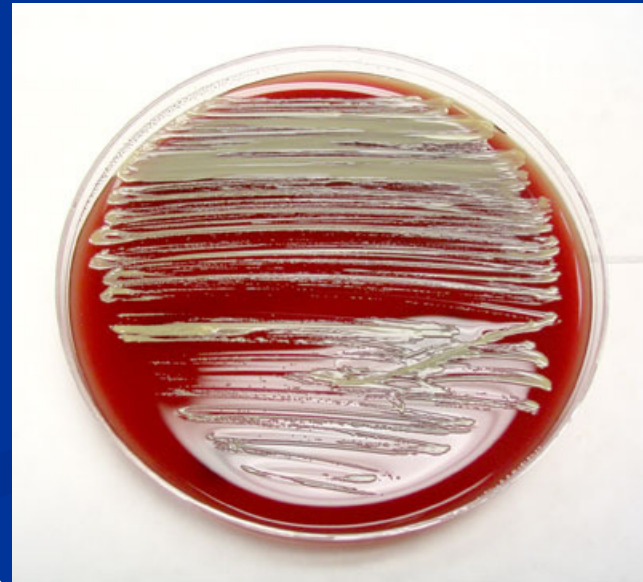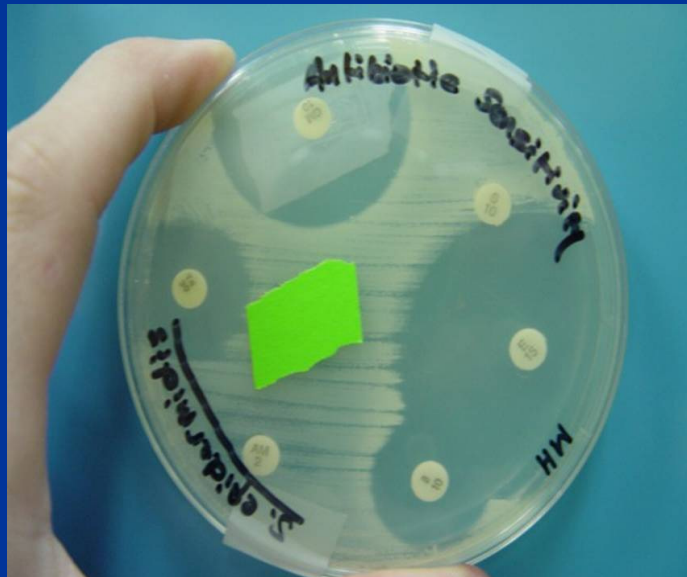
DENDRITIC CELL THERAPY – INDIAN EXPERIENCE

DR. JAMAL A. KHAN

MBBS, MD

**DIRECTOR
INSTITUTE OF CELLULAR THERAPIES
NOIDA**

ICT, J-3 Sec 41, Noida



IMMUNOLOGY

- STEROIDS
- VACCINES

IMMUNOLOGY

- STEROIDS- AUTOIMMUNE DISORDERS
- VACCINES- SMALL POX, DIPHTHERIA, TETANUS, RABIES


ICT, J-3 Sec 41, Noida

CANCER - NATURAL CHECKS

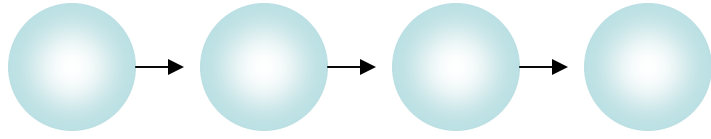
MUTATIONS

CHECKED BY

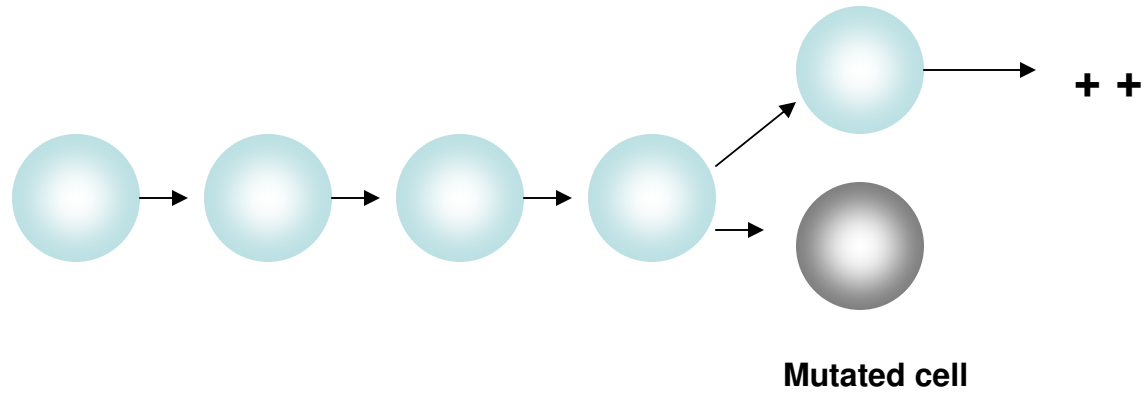
NATURAL (INNATE) AND ACQUIRED IMMUNITY

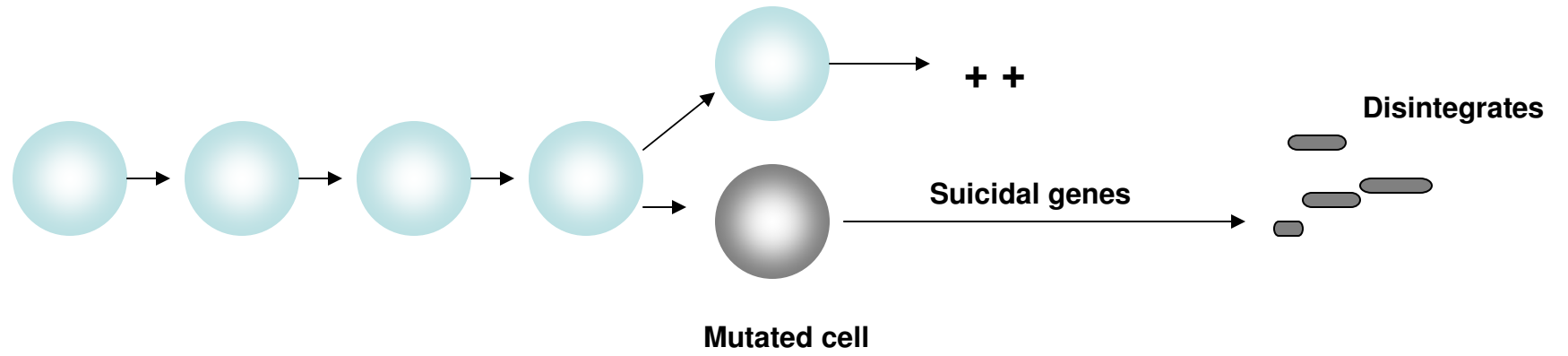


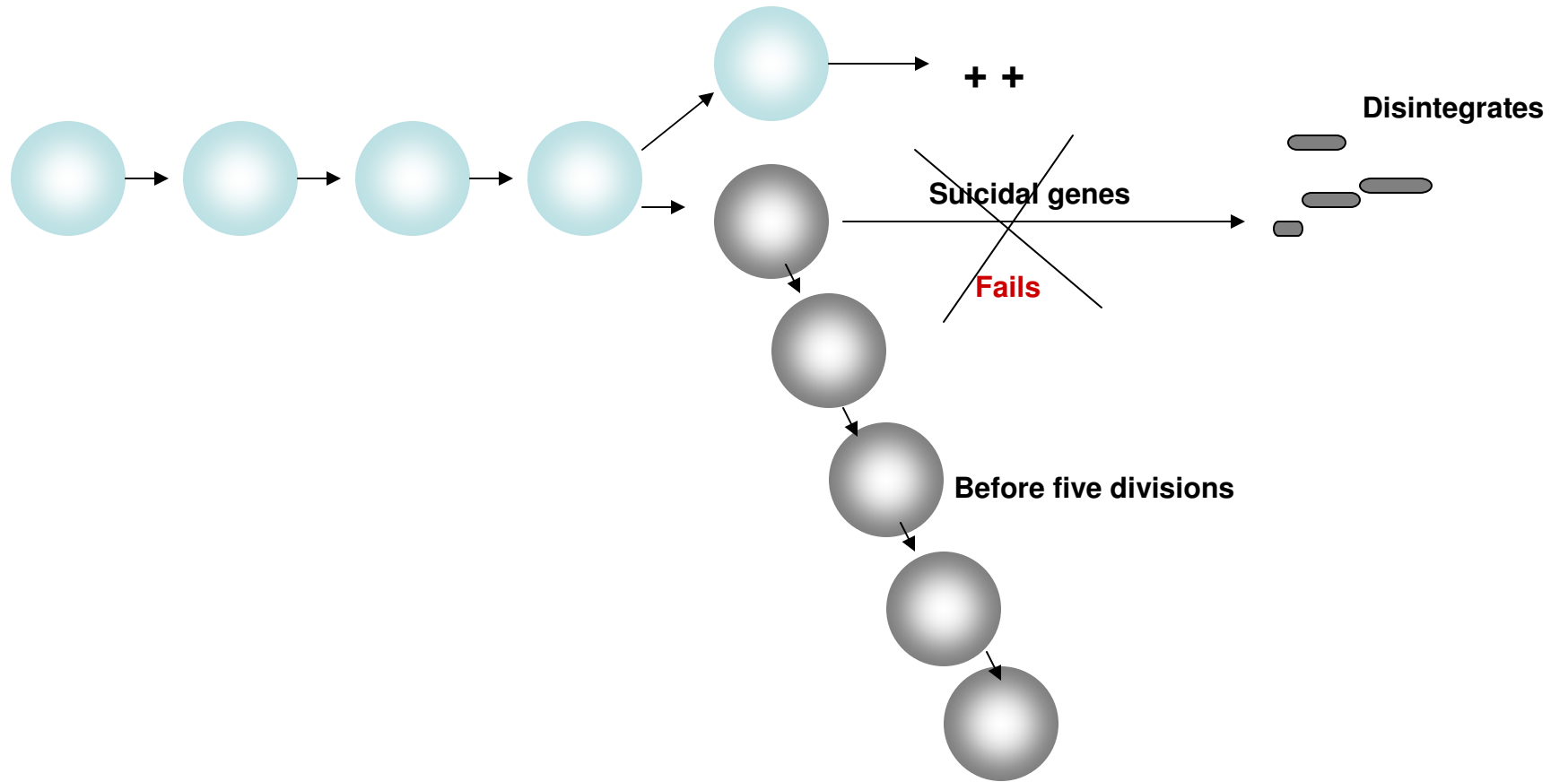
Normal cell

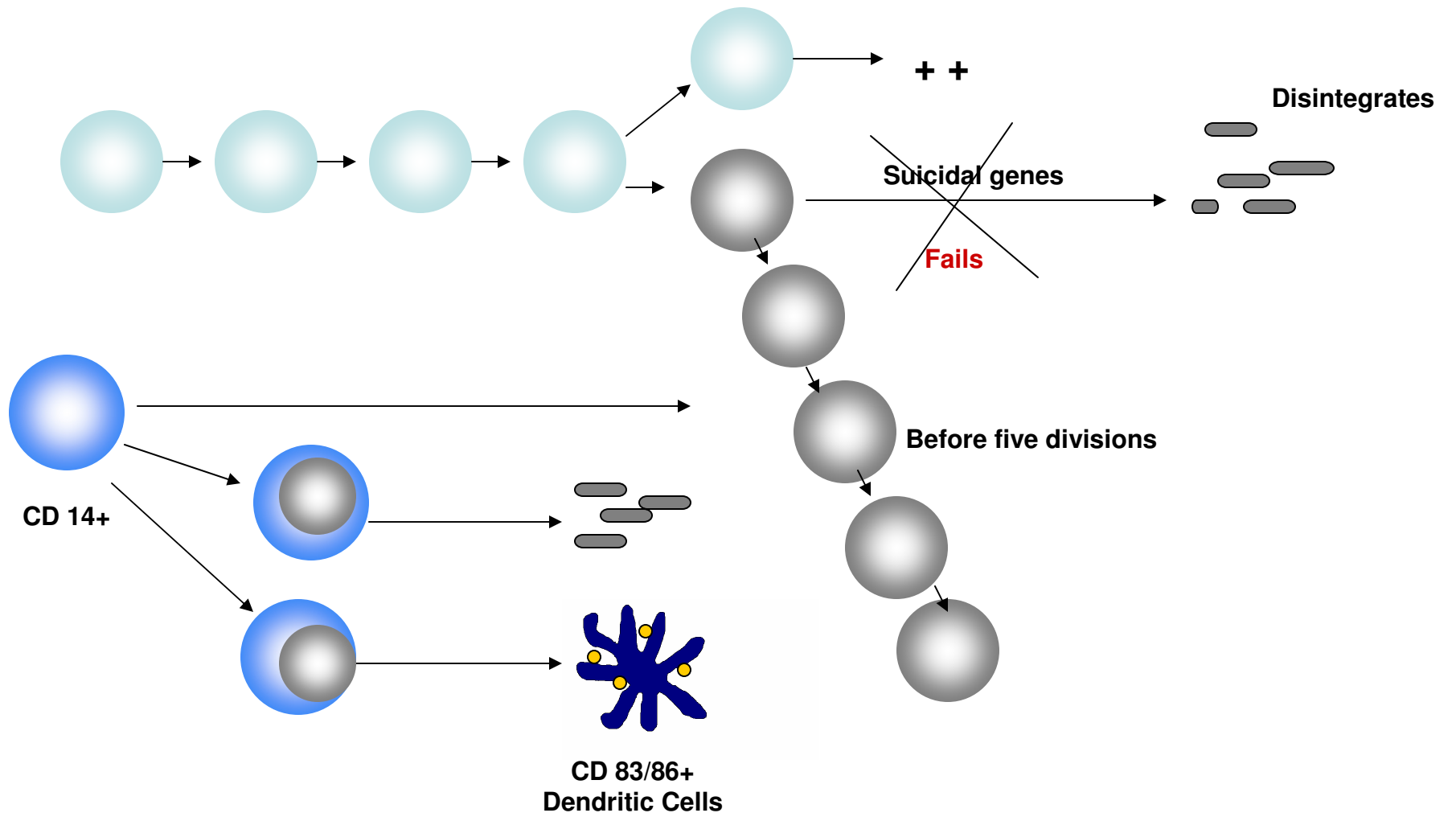


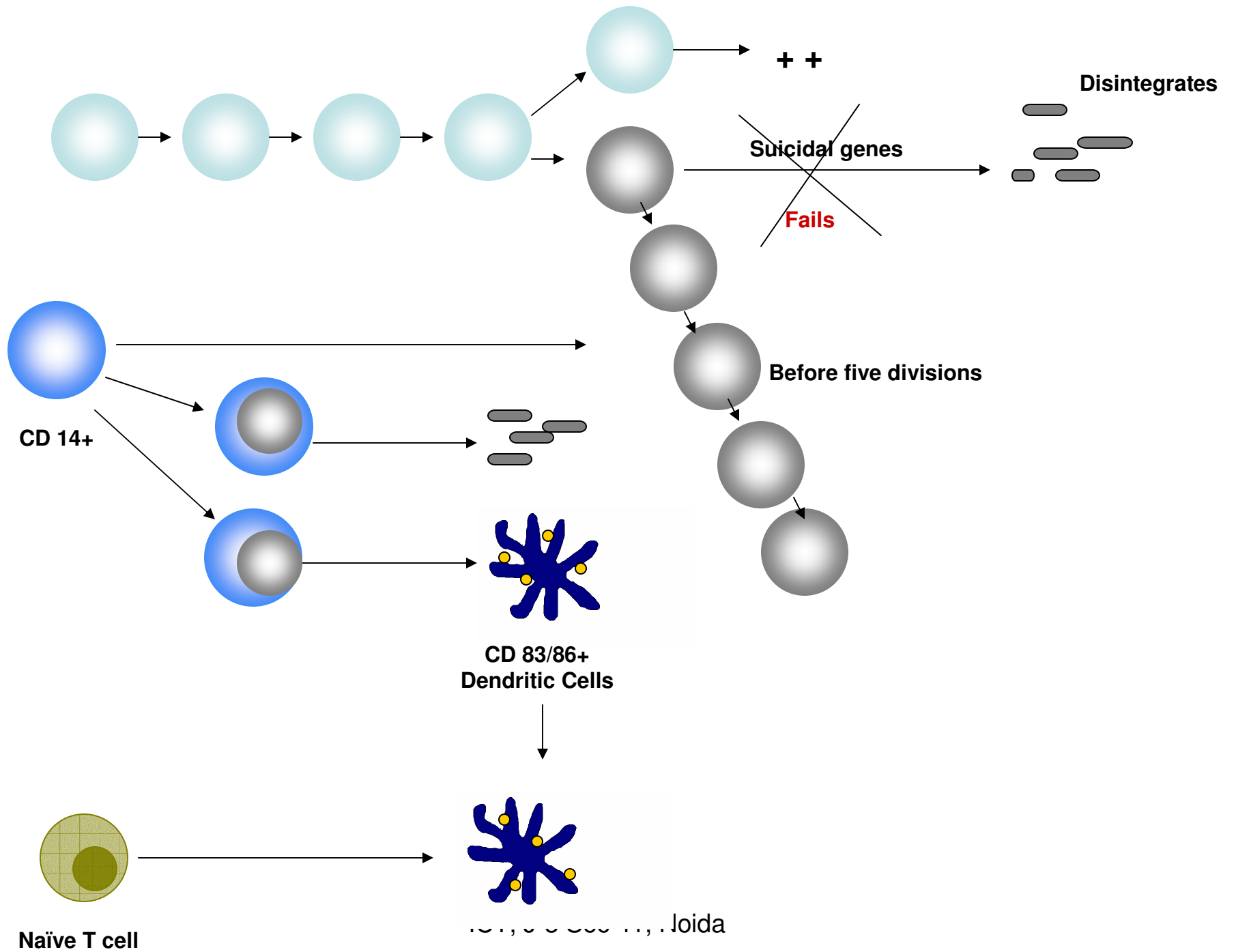
ICT, J-3 Sec 41, Noida

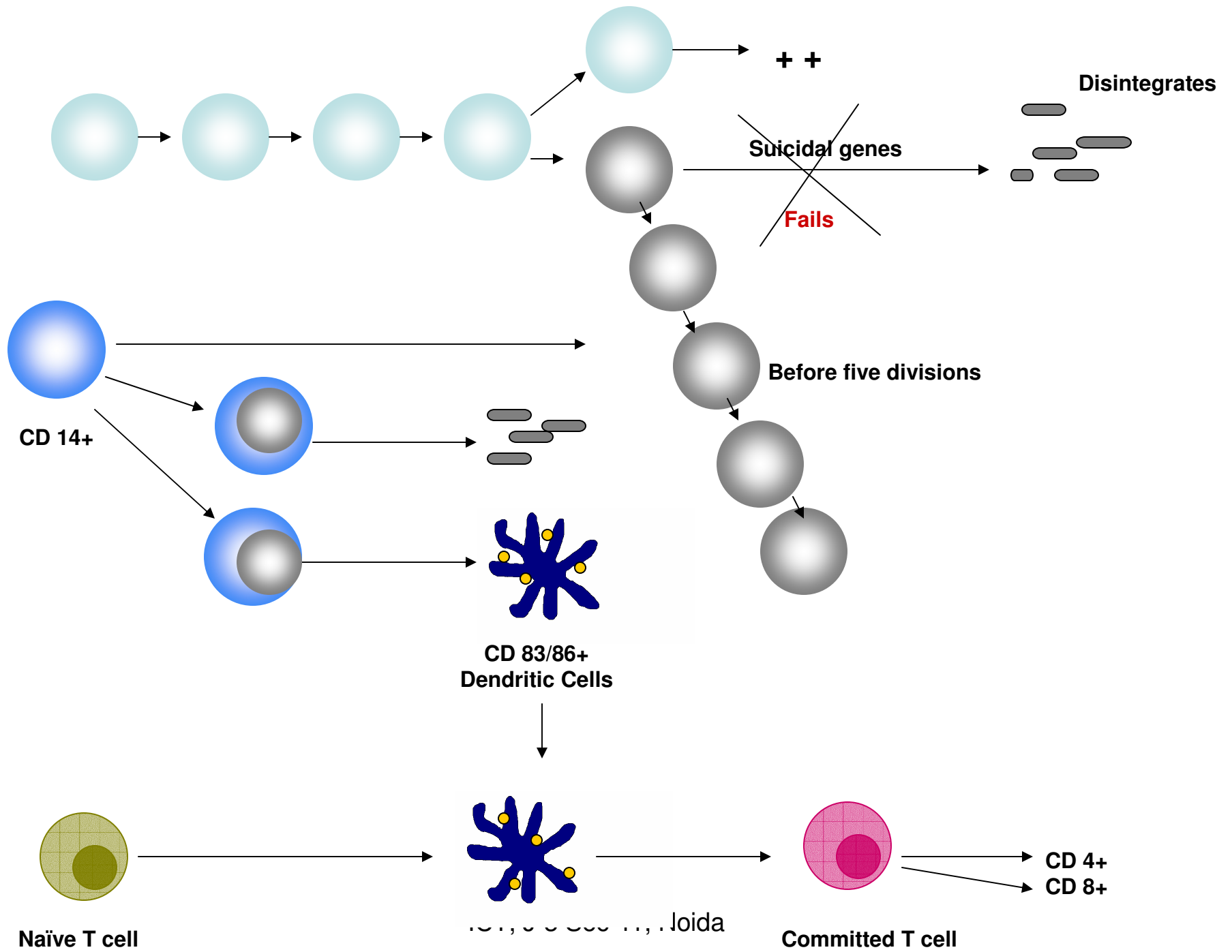


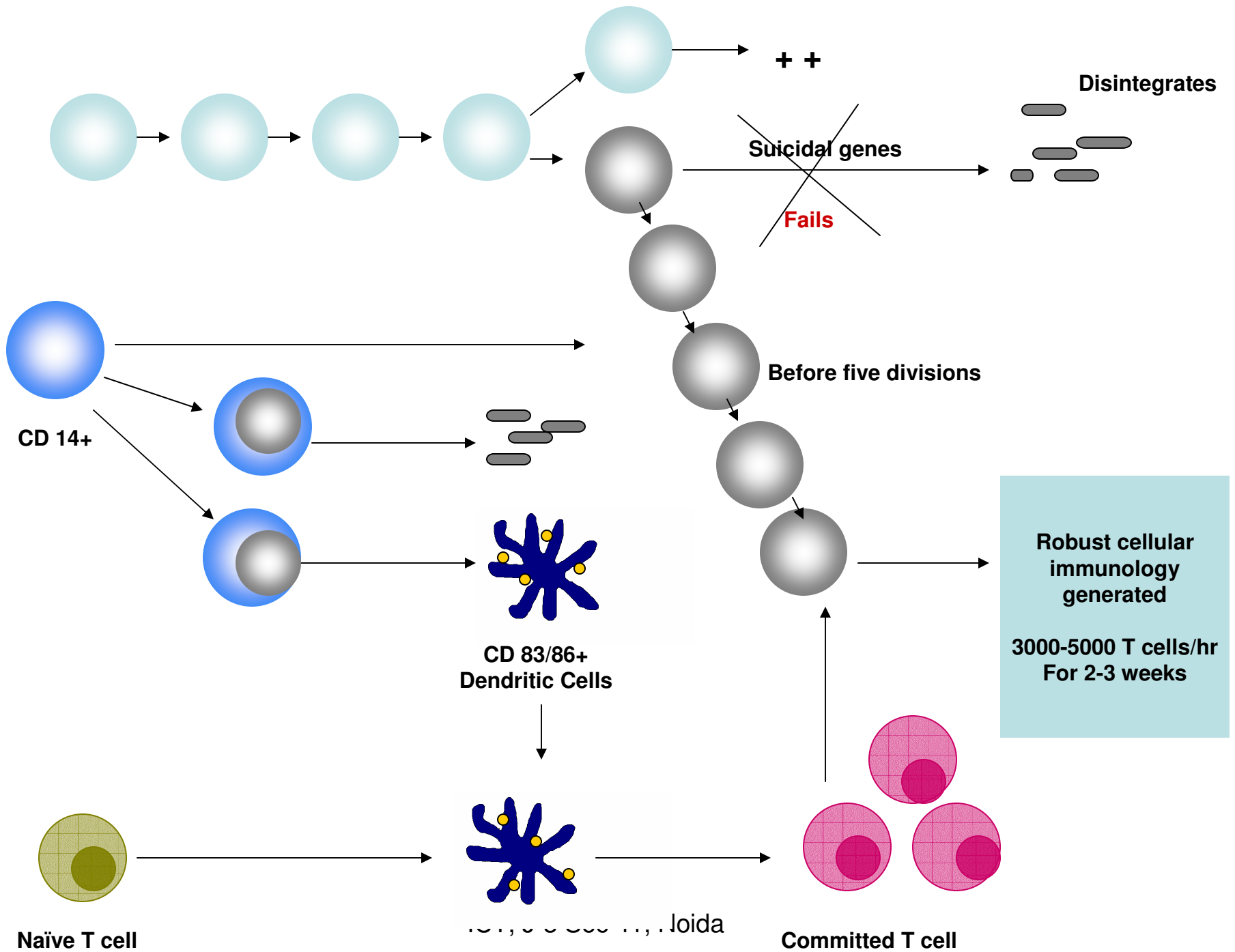






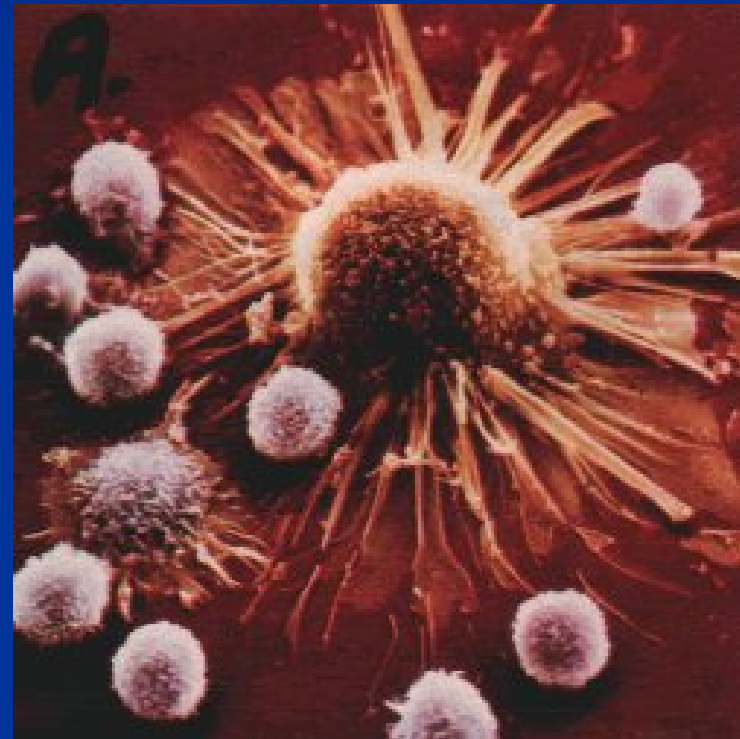



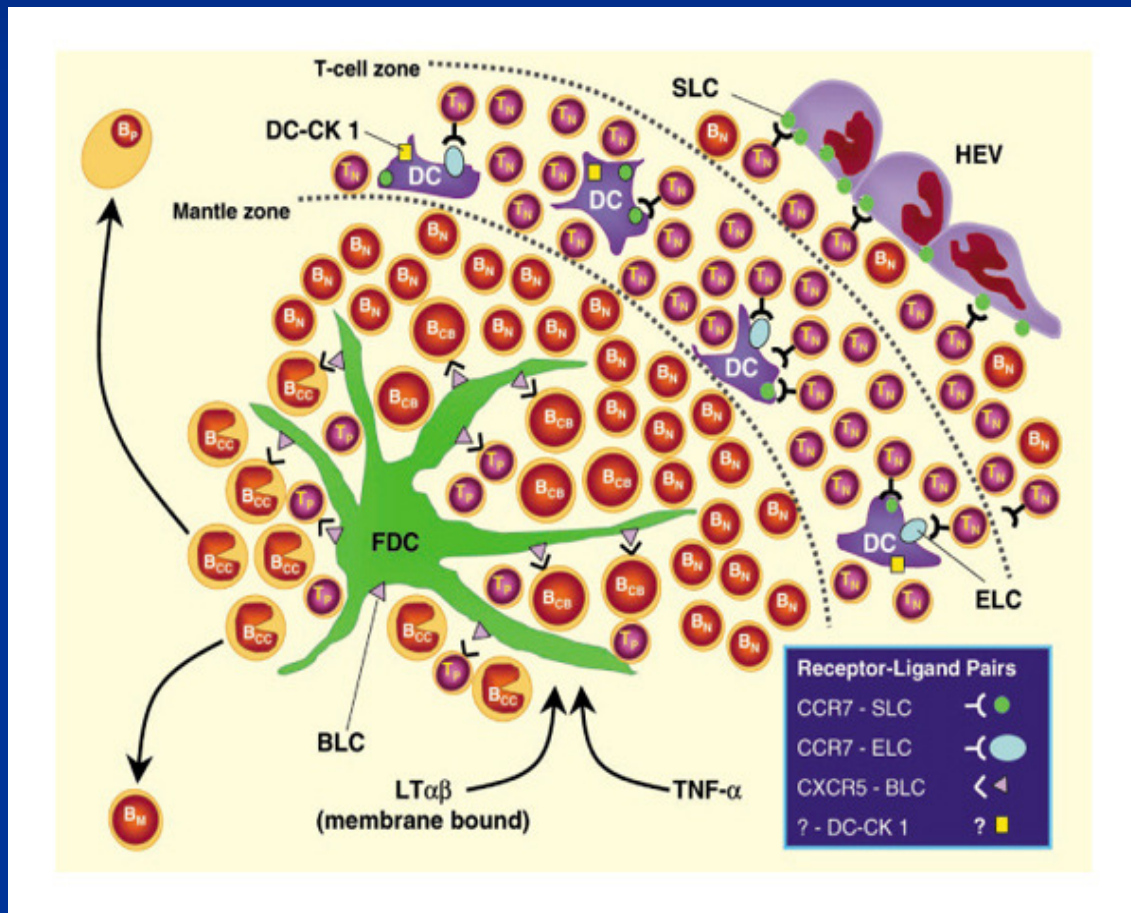


CHEMOTHERAPY

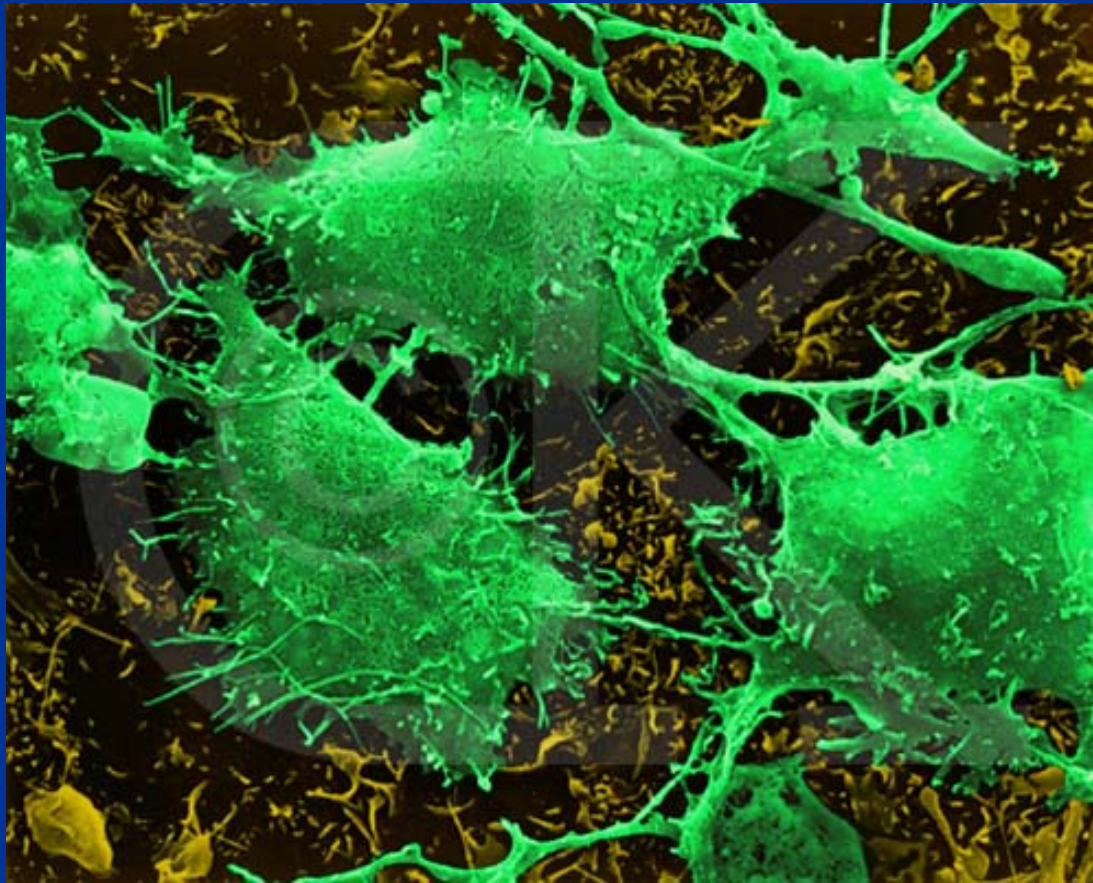
- Helps in rebuilding immunity
- Exposes internal epitopes of cancer cell to immune cells



CANCER SURVIVORS



When reactivation of
immunology fails-
it results in relapses



ICT, J-3 Sec 41, Noida

WHEN CR IS ACHIEVED

CAN WE DEVELOP IMMUNE CELLS IN THE LAB AND RE-ADMINISTER THEM TO CONTRIBUTE TOWARDS NATURAL IMMUNOLOGY?

YES – WE HAVE DEMONSTRATED IT IN CLINICAL TRIALS

ICT, J-3 Sec 41, Noida

PILOT STUDIES

44 YRS/ FEMALE WITH H/O SURGERY OF
CHOLANGIOCARCINOMA (2006) FOLLOWED BY
CHEMO/RADIATION

DEVELOPED CHEST WALL METASTASIS –
REOPERATED (2007)

OPTED FOR DENDRITIC CELL THERAPY

NO NEW LESIONS AND PET-CT CONFIRMED FREE OF
DISEASE IN 2009

PATIENT OF RECURRENT CA MASTOID

OPERATED THREE TIMES WITHIN A SPAN OF
18MTHS AND RECEIVED CHEMO/RADIATION

AFTER THIRD SURGERY (2006) STARTED DC
THERAPY

GIVEN 6 MONTHLY DOSES

NO RECURRENCE TILL LAST EVALUATION IN
2009

CA OVARY (SEROUS CA125 MARKER + GROUP)

12 PATIENTS WERE GIVEN DC THERAPY AT
MICROMETASTASIS

STAGING JUDGED ON THE BASIS OF RISING
TITER

NO RADIOLOGICAL EVIDENCE OF DISEASE
IN 9 PATIENTS AFTER 2 YEARS

Patient of Resected CA Gallbladder with nodal metastasis (unresected)

DC THERAPY STARTED in 2005

MONTHLY DOSES WERE GIVEN FOR 18 MONTHS

NO RADIOLOGICAL EVIDENCE OF NEW LESIONS

MALIGNANT LESIONS REMAINED STATIC GIVING US AN
IMPRESSION OF TOMBSTONES

GAP BETWEEN TWO VACCINES INCREASED TO 4 MONTHS AND
DISEASE RELAPSED WITH MALIGNANT ASCITES

DC THERAPY FOR PALLIATION

- CHONDROSARCOMA
- OSTEOSARCOMA
- MULTIPLE MYELOMA
- CA COLON
- HCC
- CA STOMACH
- GBM

DC IN RENAL CELL CA

- UNRESECTABLE RCC WITH METASTASIS
- STABLE DISEASE FOR 1.2 YEARS
- SYMPTOMATIC BENEFIT

FUTURE

- RANDOMIZED TRIALS TO BE CONDUCTED IF POSSIBLE
- PATIENTS OF CR/PROGRESSIVE DISEASE/ADVANCED STAGES BE GIVEN AN OPTION OF DC THERAPY
- LET US TRY IT AT LARGER SCALE AND AT MULTIPLE CENTERS TO GATHER MORE STATISTICS

LET'S MAKE A
BEGINNING

THANKS